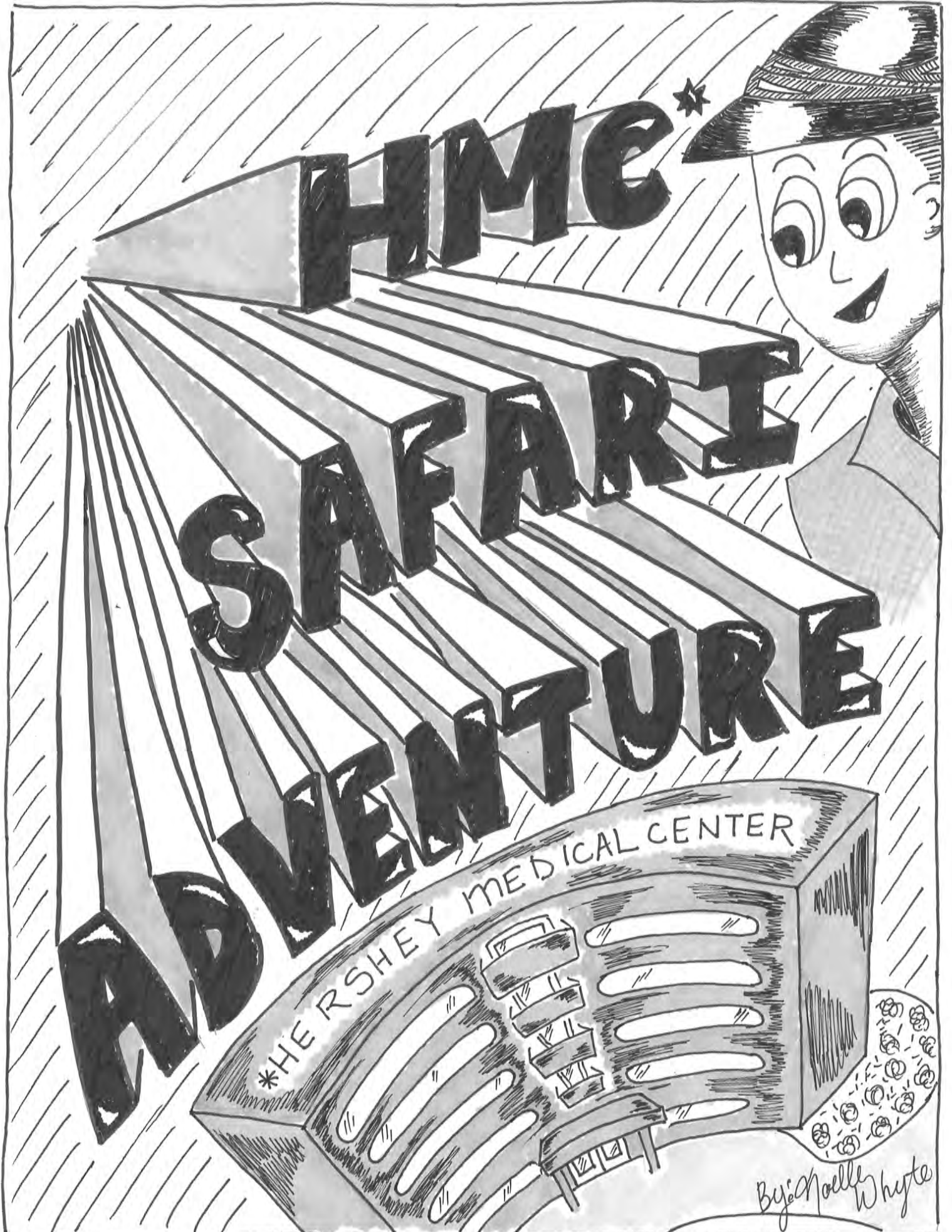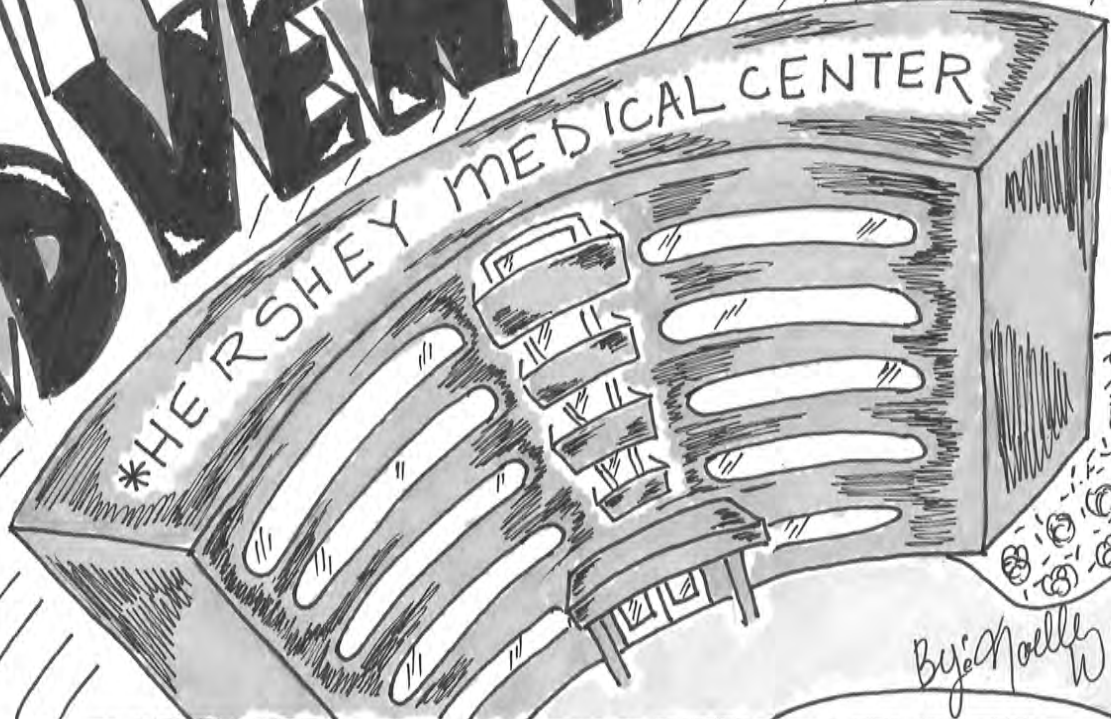









HOME

SAFARI

ADVENTURE



By: Noelle Whyte




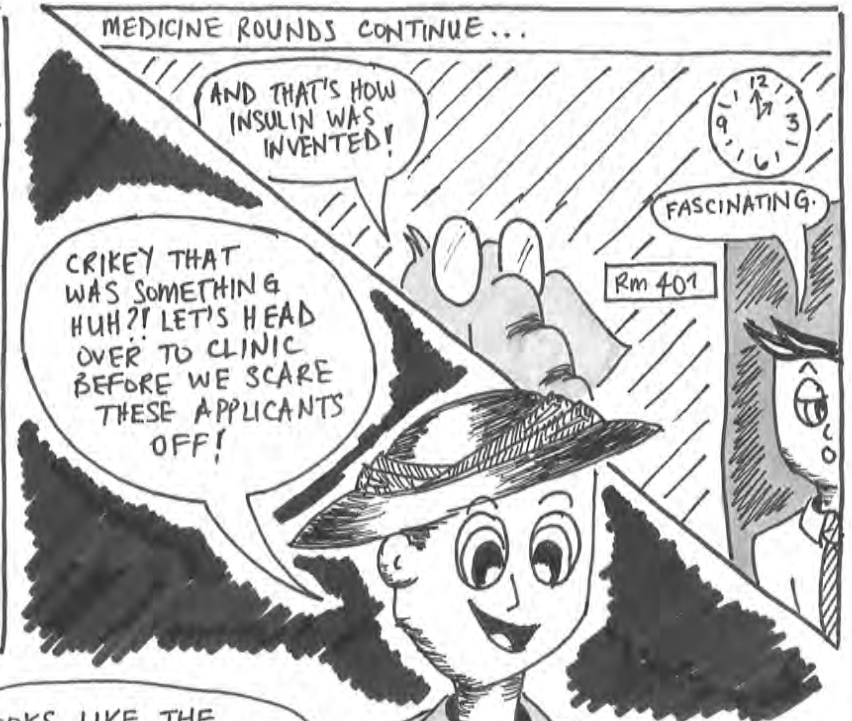
WISER ATTENDING PHYSICIAN \*INFLAMMATORY BOWEL DISEASE

ASTUTE MEDICAL STUDENT

BEWILDERED MEDICAL STUDENT

DEFEATED MEDICAL STUDENT

INTIMIDATING SURGEON NERVOUS MEDICAL STUDENT



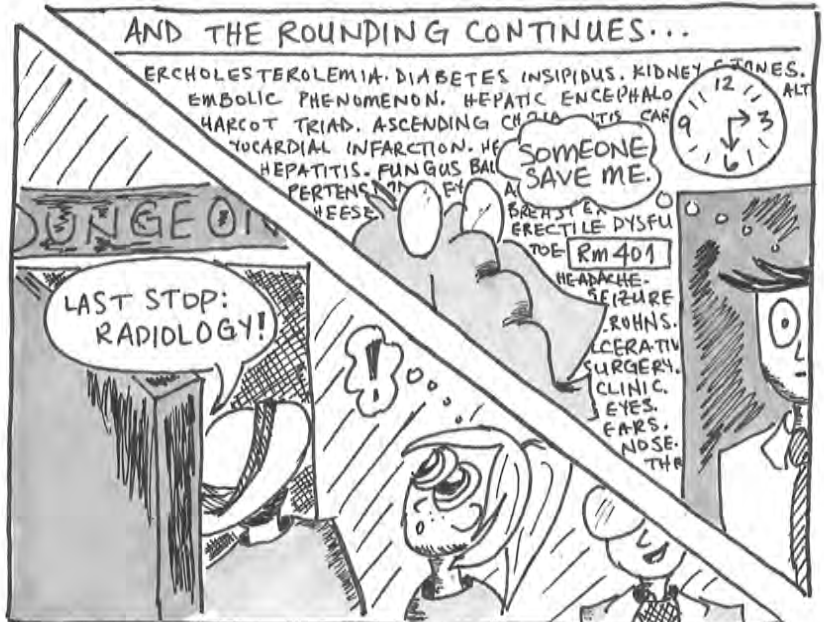CHILDISH PICTURES ON CLINIC WALL



HEEY THERE KIDDO!

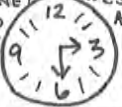

CRIKEY, THEY SURE CAN WAIL HUH? LET'S HEAD BACK TO THE HOSPITAL NOW.




AND THE ROUNDING CONTINUES...

ERCHOLESTEROLEMIA. DIABETES INSIPIDUS. KIDNEY STONES. EMBOLIC PHENOMENON. HEPATIC ENCEPHALO HARCOT TRIAD. ASCENDING CHOLICITIS CAR VUCARDIAL INFARCTION. HE HEPATITIS. FUNGUS BALL PERTENSION OF EYAL BREAST ERECTILE DYSFU TOE RM 401 HEADACHE SEIZURE ROHNS. ULCERATIN SURGERY. CLINIC. EYES. EARS. NOSE. TH



SOMEONE SAVE ME.

LAST STOP: RADIOLOGY!



SO AS YOU CAN SEE, THE RADIOLOGISTS ARE HARD AT WORK!

ACTUALLY, WE CAN'T REALLY SEE ANYTHING

OH! HOW COULD I FORGET THE LIGHTS?!



CLICK!




TOO MUCH LIGHT!!

IT BURNS!!



CRUIKEY THAT WAS EXCITING!  
WELL THAT CONCLUDES OUR  
TOUR. I HOPE YOU ENJOYED  
IT AND SAW A BIT  
OF WHAT YOU'RE  
IN FOR!



I FEEL ODDLY  
DRAWN TOWARDS  
RADIOLOGY

I WONDER IF  
IT'S TOO LATE TO  
CONSIDER SWITCHING  
CAREERS?

**THE  
END**