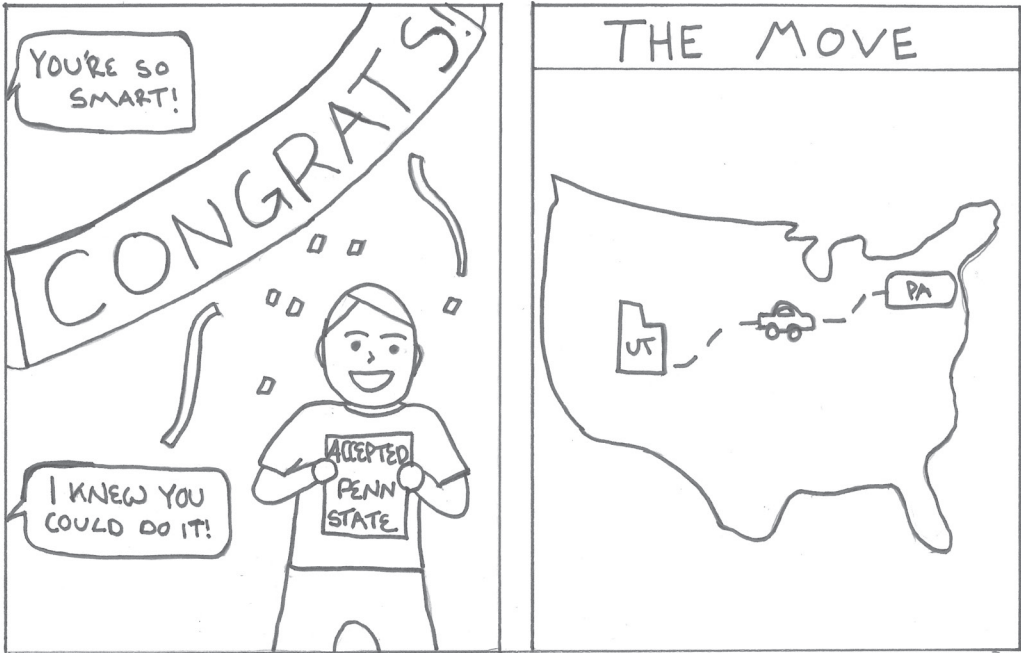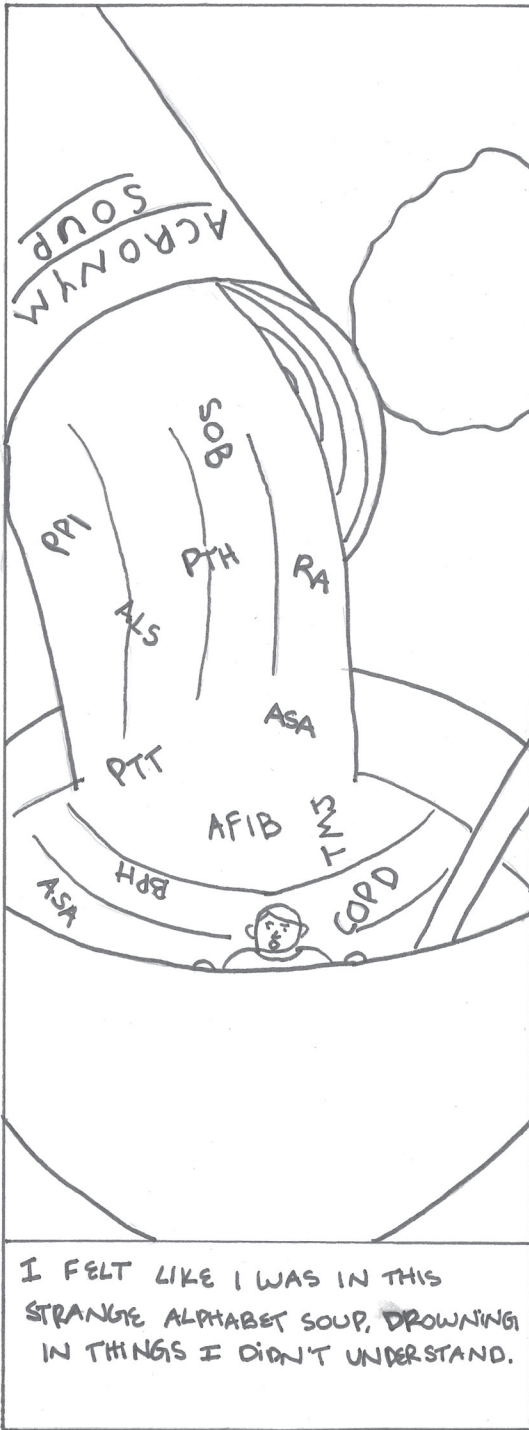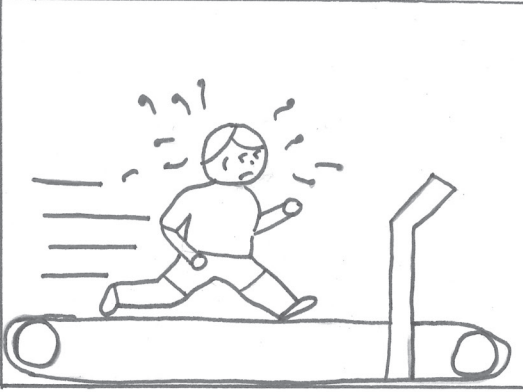



I REDOUBLED MY EFFORTS, UNFORTUNATELY, I STILL FELT I WAS RUNNING IN PLACE.



AS I STARTED 3rd YEAR CLERKSHIPS I FELT LIKE MY STUDYING WAS ALL IN VAIN.




HE'S ON AN ECMO STATUS POST CARGI, WHAT IS HIS PEEP AGAIN?

... Uh I DIDN'T ASK ABOUT PEEPS...



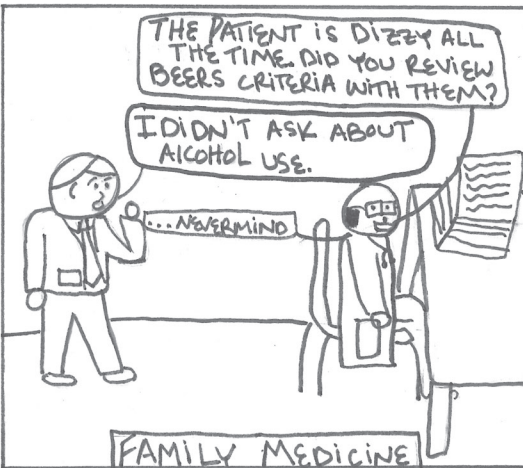
MAKE SURE TO ASK ABOUT HER P's + G's!



THE PATIENT IS DIZZY ALL THE TIME. DID YOU REVIEW BEERS CRITERIA WITH THEM?

I DIDN'T ASK ABOUT ALCOHOL USE.

... NEVERMIND





I THOUGHT THAT NEAR THE END OF 3rd YEAR I WOULD FEEL MORE CONFIDENT... I DIDN'T

WHAT'S THE DIFFERENCE BETWEEN DTAP & Tdap?

WHEN WILL THE ACRONYMS STOP!!





4th YEAR MEANT BOARDS, MORE ROTATIONS & NEARING BECOMING A REAL DOCTOR

CALENDAR

STEP 1	CARDS	ANESTHESIA
EMERGENCY MEDICINE	STEP 2	RADIOLOGY
GI	INTERVIEWS	INTERVIEWS
SICU	GRADUATION	INTERN YEAR



MR. P 44yr MALE

HISTORY	VITALS	MEDS	IMAGING
DSLL	BP 120/88	~~~~~	CT SCAN
OPEN	HR 97	~~~~~	CXR
OTRACH	RR 18	~~~~~	CXR
ONASH	SPO2 97% ON 2L	~~~~~	US
OPM2		~~~~~	
OMETSTO		~~~~~	
BRAIN		~~~~~	
ODYSPHAGIA		~~~~~	

AFTER REVIEWING THE CHART & SEEING THE PATIENT I CALLED THE FELLOW.

HELLO!

HEY! CAN I STAFF THIS PATIENT WITH YOU?

SURE!

HE'S A BIT COMPLICATED SO I'M SORRY IF IT'S A BIT JUMBLED...

64 YR OLD MALE WITH HX OF SCL WITH METS TO THE MEDIASTINUM & BRAIN, DM2, NASH CIRRHOSIS, & DYSPHAGIA. HE'S TRACHED, PELTID...
ON PPI

PT/WR IS...

HE HAD A CTA THAT SHOWED...

PEEP IS AT... MRI HAD...

M/GU SAID...

IN SUMMARY, FROM A GI STANDPOINT I THINK...
WHAT ARE YOUR THOUGHTS?

FIRST OFF, GREAT PRESENTATION I AGREE WITH YOUR ASSESSMENT, GREAT WORK! WE CAN STAFF THEM THIS AFTERNOON WITH DR. SCOPE

AWESOME! THANKS!

MAYBE I HAVE MADE SOME PROGRESS!!



OFTENTIMES MED SCHOOL FEELS LIKE YOU ARE RUNNING IN PLACE, MAKING NO PROGRESS, STUDYING ALL THE TIME, & LEARNING NOTHING. STAY THE COURSE, AT THE END, ALL THE LATE NIGHTS TURN INTO A MOMENT OF CLARITY THAT YOU ARE MAKING PROGRESS.

-BRONSON KUNZLER,
MS4